

## CASE REPORT

# Sigmoid looping is not always benign

Yasir M. Khayyat <sup>1, 2</sup>, Khaled M. Gabr <sup>2</sup>, Ramy G. Makary <sup>2</sup>

1. Department of Medicine, Faculty of Medicine, Umm AlQura University, Makkah, Saudi Arabia. 2. Department of Medicine, International Medical centre, Jeddah, Saudi Arabia.

**Correspondence:** Yasir M. Khayyat. Address: P.O Box 2172, Department of Medicine, International Medical Centre, Jeddah 21451, Saudi Arabia. Email: yasirkhayyat@hotmail.com

**Received:** February 11, 2014

**Accepted:** May 15, 2014

**Online Published:** May 19, 2014

**DOI:** 10.5430/crim.v1n2p146

**URL:** <http://dx.doi.org/10.5430/crim.v1n2p146>

## Abstract

Colonoscopy is a daily procedure that has limited risk if carried out by skilled endoscopists. Unexpected turn of events during the procedure requires careful consideration of the patient's underlying medical or surgical history. Here, we present a case of inability to withdraw the colonoscope after the completion of distal colonic intubation owing to an overseen surgical defect related to inguinal hernia in which entrapment of the colonoscope took place.

## Keywords

Inguinal, Hernia, Colonoscopy, Complication

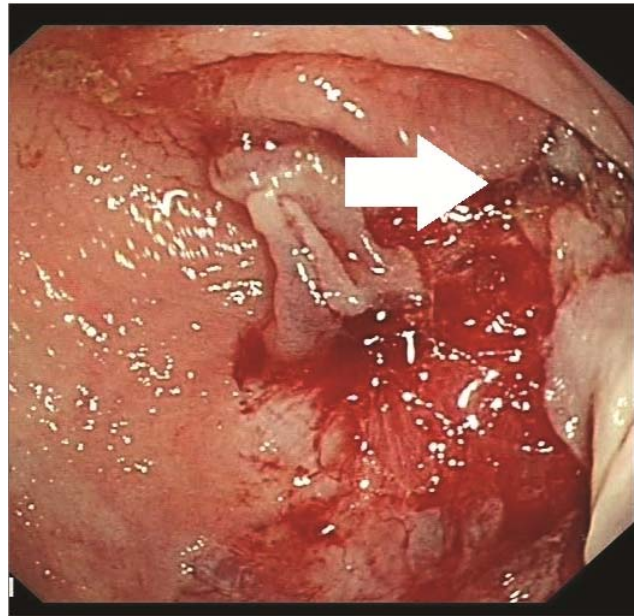
## 1 Introduction

Endoscopic procedures are performed on a daily basis as a low risk surgical intervention, and generally present a low rate morbidity and mortality. Furthermore, these procedures produce less adverse events, when compared with invasive major surgical procedures. Performance of elective endoscopic procedures in the elderly group deserves careful selection, especially with the frequent cardiac and pulmonary co-morbidities and the underlying aging process of the bowel mesenchymal layers. As endoscopic-related complications are becoming less uncommon, several approaches are being developed to minimize such complications during the pre-procedural phase, which includes relevant history and physical examination, along with consultation with the anesthetist for choosing appropriate sedatives needed for each procedure. The endoscopist must be vigilant and aware of the possible complications that may arise during the procedure and act promptly to manage it accordingly, with special consideration to the age related changes, by taking appropriate measures. Some include a first presentation of a medical or surgical condition during endoscopy. In this case report, we present a successfully managed entrapped colonoscope loop within a large inguinal hernia.

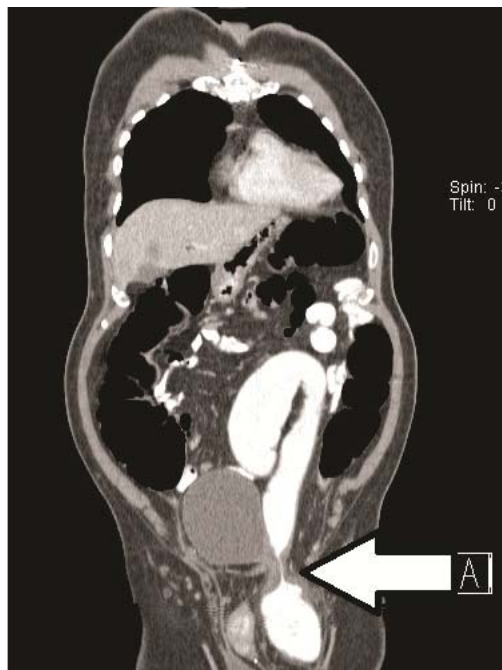
## 2 Case presentation

A 70-year-old male patient with hypertension, type 2 diabetes, ischemic heart disease, and recent altered bowel movements with persistent constipation, was admitted for endoscopy. Laboratory work showed normal liver panel, CBC, and coagulation profile, but positive stool for occult blood. Upper and lower endoscopies performed under conscious sedation using intravenous Midazolam and Propofol administered by Anesthesiologist. Upper endoscopy showed mild gastritis and duodenitis. Subsequently, the patient was positioned for colonoscopy, The bowel preparation was optimal,

Upon visualization there was a small sessile polyp of 7 cm was noted at the anal verge. Unfortunately, there was a large cauliflower-like infiltrating circumferential mass that was partially obstructing the lumen of the rectosigmoid area. During colonoscopy, the presence of a markedly acute angle (see Figure 1) 40 cm from the anal verge made the passage the scope difficult. With different maneuvers and torqueing, the scope could reach only the ascending colon. Upon withdrawal, the scope was jammed and it was difficult to extubate; however, further maneuvering using abdominal pressure and gentle sequence of advance and withdrawal resulted in successful extubation. Some lacerations were noted thereafter.



**Figure 1.** Endoscopic view showing markedly narrow lumen where the expected hernia sac is encountered.



**Figure 2.** CT scan of the chest, abdomen and pelvis, White arrow “A” at the neck of the left inguinal hernia sac with contrast filling the colonic lumen after colonoscope removal.

Abdominal X-ray performed after the colonoscopy revealed no evidence of perforation, but exhibited evidence of distended bowel. CT scan of the abdomen showed short segment of circumferential mural mass at the rectosigmoid colon associated with perirectal fat and lymph nodes. Furthermore, left inguinal hernia containing part of the sigmoid colon that measures 11 cm in length with 3 cm diameter at the hernial sac and right inguinal hernia containing omental fat were noted (see Figure 2), which explained the difficulty encountered during colonoscopy extubation.

### 3 Discussion

Colonoscopy is a safe procedure performed in patients of different age groups. Its course depends on an intact mural integrity of the mucosal and serosal surfaces as well as on the supporting mesentery. It is known that the mesocolon of the sigmoid and transverse segments is loose. This loose sigmoid mesocolon and the presence of adjacent peritoneal defects such as abdominal hernial defects could lead to passage of the colonic contents into this lower pressure segment such as hernia defects. With regard to adverse events related to colonoscopy, a systemic review showed that the risk increases with the age above 65 years and further increases in octogenarians (aged 80–89 years). The cumulative gastrointestinal complications reported are 26 per 1000 individuals, and the rates of complications such as perforation, gastrointestinal bleeding, and cardiopulmonary problems are 1, 6.3, and 19 per 1000 individuals, respectively. The reported incidence of mortality is 1 in 1000 individuals. When compared with the other age groups, cardiopulmonary complications have been noted to be higher in octogenarians (up to 28.9 per 1000 individuals)<sup>[1]</sup>. Considering the possibility of herniation of the bowel contents, such as a colonoscope passed into a hernial defect, it would be expected that adequate space is necessary to allow the passage of the scope into a hernial sac. It has been found that an average of 3–6cm circular defect at the neck of the hernial sac is the diameter that allows passage of a standard adult colonoscope and been trapped within<sup>[2]</sup>. Several cases of incarcerated inguinal hernia that had led to difficulty in colonoscopy have been reported in the literature with different presentations that occurred during and after colonoscopy; some were brief, while others led to bowel ischemia and ulcerations<sup>[3]</sup>. Incarceration of inguinal hernia within a loop of the bowel has been reported to have occurred even after the completion of colonoscopy<sup>[4]</sup>, thus expanding the possibility of post-procedural side effects such as intestinal ischemia. Earlier, it had been presumed that bilateral inguinal hernia is associated with colorectal cancer, making colonoscopy necessary in those cases; however, this idea has been refuted in several case series<sup>[5, 6]</sup>, thus leaving the decision on individual judgment.

With regard to the management in the event of entrapped colonoscope, several possible methods for the extubation of the colon and removal of the colonoscope have been reported, which include removal of the colonoscope tip with gentle and gradual pull under fluoroscopic guidance, application of manual external pressure with the patient positioned on his/her back and use of the “Pulley technique” aimed at fixing the loop created at the hernia sac, holding the inner loop with the thumb and index finger while the colonoscope is withdrawn<sup>[2, 7, 8]</sup>. To date, there are no reported cases in the literature, which needed surgical intervention to remove the entrapped colonoscope. Therefore, prior to performing endoscopic procedures, it is advisable to review the patient’s surgical history, in general, especially prior to colonoscopy or enteroscopy, to avoid unexpected events, the outcomes of which are difficult to predict.

### References

- [1] Day, L. W., Kwon, A., Inadomi, J. M., Walter, L. C. and Somsouk, M. Adverse events in older patients undergoing colonoscopy: a systematic review and meta-analysis. *Gastrointest Endosc.* 2011; 74(4): 885-896. <http://dx.doi.org/10.1016/j.gie.2011.06.023>
- [2] Koltun, W. A. and Collier, J. A. Incarceration of colonoscope in an inguinal hernia. " Pulley " technique of removal. *Dis Colon Rectum.* 1991; 34(2): 191-193. <http://dx.doi.org/10.1007/BF02049997>
- [3] Chong, V. H., Jamaludin, A. Z. and Mackie, H. A. Lower gastrointestinal bleeding: an unusual manifestation of inguinal hernia. *Hernia.* 2008; 12(4): 431-432. <http://dx.doi.org/10.1007/s10029-008-0333-9>
- [4] Patterson, R. and Klassen, G. Small bowel obstruction from internal hernia as a complication of colonoscopy. *Can J Gastroenterol.* 2000; 14(11): 959-960.

- [5] Akbaba, S., Ersoy, E., Gundogdu, H. and Yasar, U. Is a routine preoperative rectosigmoidoscopy necessary in patients with bilateral inguinal hernia? Bratisl Lek Listy. 2012; 113(10): 604-606.
- [6] Avidan, B., Bardan, E., Lang, A., Fidler, H. H., Chowers, Y. and Bar-Meir, S. Colorectal cancer screening in patients presenting with an inguinal hernia: is it necessary? Gastrointest Endosc. 2004; 59(3): 369-373.  
[http://dx.doi.org/10.1016/S0016-5107\(03\)02715-9](http://dx.doi.org/10.1016/S0016-5107(03)02715-9)
- [7] Tan, V. P., Lee, Y. T. and Poon, J. T. Incarceration of a colonoscope in an inguinal hernia: Case report and literature review. World J Gastrointest Endosc. 2013; 5(6): 304-307. <http://dx.doi.org/10.4253/wjge.v5.i6.304>
- [8] Punnam, S. R. and Ridout, D. Incarcerated inguinal hernia. Gastrointest Endosc. 2003; 58(5): 757-758.  
[http://dx.doi.org/10.1016/S0016-5107\(03\)02021-2](http://dx.doi.org/10.1016/S0016-5107(03)02021-2)